



Bir Çocukta Künt Travma Sonrası Torasik Özofagus Rüptürü: Gecikmiş Tanı ve Cerrahi Tedavisi

Thoracic Esophageal Perforation After
Blunt Trauma in a Child: A Delayed Diagnosis and Surgical Management

Thoracic Esophageal Perforation After Blunt Trauma in a Child / Bir Çocukta Künt Travma Sonrası Torasik Özofagus Rüptürü

Alper Avcı, Sevval Eren, Bulent Ozturk

Thoracic Surgery Department, Faculty of Medicine, Dicle University, Diyarbakır, Turkey.

Özet

Künt travmaya bağlı gelişen özofagus rüptürü çocuklarda çok nadirdir. 13-yaşında-erkek çocuk acil serviste 3 metre yüksekten düşme sonrası üzerine kütük düşmesi sonrası 4. saatinde nefes darlığı ve karın ağrısı ile başvurdu. Hastaneye yatışının 6. gününde özofagus rüptürü tanısı kondu ve 7. Gün sağ torakotomi ile opere edildi. Kas ve mukosa debridmanı sonrası özofagus katları sütüre edildi ve sütür hattı plevra ve interkostal kas flebi ile desteklendi. Perforasyonun alt ve üst ucu emilebilir katgut sütür ile bağlandı ve özofageal pasaj durduruldu. Beslenme için gastrostomi ve jejunostomi açıldı. Burada gecikmiş tanı alan ve cerrahi olarak başarılı şekilde tedavi edilen özofagus rüptürünü sunmaktayız.

Anahtar Kelimeler

Özofagus Rüptürü, Çocuk, Toraks Travması, Cerrahi.

Abstract

Esophageal rupture due to external blunt trauma is extremely rare in children. A-13-year old boy was admitted to emergency room with shortness of breath and abdominal pain. His history revealed fall down from 3 metres height, falling of a wooden block over chest, 4 hours before at home. Thoracic esophageal perforation was diagnosed at the 6th day of hospital stay. Surgical management was planned and right-sided thoracotomy was performed at the 7th day after admission. The esophageal layers were closed primarily and separately after muscular and mucosal debridement. Reinforcement of the primary repair was done with pleural and intercostal muscle flaps. The esophagus was tied with absorbable sutures at proximal and distal parts of the perforation to block the esophageal passage. Gastrostomy and jejunostomy were performed for nutrition. We report here a successful management with primary repair of this esophageal perforation of late diagnosis.

Keywords

Esophageal Rupture, Child, Thoracic Injury, Surgery.

DOI: 10.4328/JCAM.10.3. 22 Received: 14.11.2009 Accepted: 11.12.2009 Printed: 01.09.2010 J.Clin.Anal.Med. 2010;1(3):44-47

Corresponding Author: Alper Avcı, Dicle University School of Medicine, Department of Thoracic Surgery, 21280, Diyarbakır, Turkey.

Phone: +90 412 2488001-16 4993 Fax : +90 412 2488520 E-mail: dralperavci@myynet.com

Intraduction

The most common causes of esophageal injuries in children are ingestion of caustic liquids and penetrating trauma, which includes iatrogenic instrumentations [1]. External blunt trauma to chest can also cause esophageal injury, though rarely. The incidence of esophageal perforation due to all blunt chest injury in children is <1% [2]. The number of cases of esophageal perforation from blunt trauma reported in the literature is less than 100. Overall mortality of esophageal perforation is about 25% [3]. Traumatic gastro-esophageal perforations are rare, and their mortality is high in children (up to 60%) [4]. Any delay in diagnosis beyond 24 hours can increase infectious complications. Delayed diagnosis and treatment are most important predictors in mortality of esophageal perforations. Successful management of esophageal perforations requires prompt and accurate diagnosis and treatment. We report a child whose diagnosis was made 6 days after the blunt chest trauma.

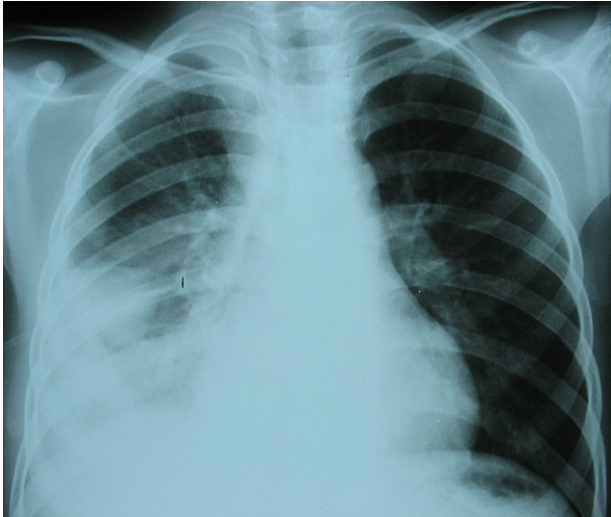


Figure 1. Plain chest radiography on admission.

Case

A-13-year old boy was admitted to emergency room with shortness of breath and abdominal pain. His history revealed fall down from 3 metres height, falling of a wooden block over chest, 4 hours before at home. On admission, the patient had a pulse of 122/min, was afebrile and the respiratory rate was 32/min. At initial clinical exam, auscultation revealed no audible breath sounds in the lower parts of the right side of the chest, and the abdomen was painful. The rest of the systemic examination was normal. White blood cell count was 21.1 K/UL (4.4-11.3). Plain radiography of neck and chest revealed right-sided hydrothorax (Figure 1). Hemothorax was diagnosed after thoracentesis, and chest tube was inserted into right pleural space. Drainage of the chest was 150 cc initially. There was blood in nasogastric tube. Radiological examination of the abdomen was normal. The patient was hospitalized into thoracic surgery clinic's intensive care unit. Broad-spectrum antibiotic treatment was started. Abdominal pain disappeared and there was no blood left in the nasogastric drainage at the second day. Nasogastric tube was removed at the third day and oral feeding was started. Chest tube was removed at the 4 th day. Fever of 38.8 centigrade degree was noted at the 5 th day. Despite treatment including broad-spectrum antibiotics, patient's fever persisted and his white blood cell count continued to rise. Thoracic Magnetic Resonance Imaging was obtained, and it showed right sided pleural effusion, of 8x5x2 cm diametered right paravertebral pus (Figure 2A and 2B). Esophagography was obtained with diluted oral contrast, and right-sided thoracic esophageal perforation was diagnosed(Figure 3) at the 6th day of hospital stay. Oral feeding was stopped, chest tube and nasogastric tube were reinserted, and total parenteral nutrition was started. Staphylococcus warnei grew in the blood culture, and antibiotherapy was changed. Despite

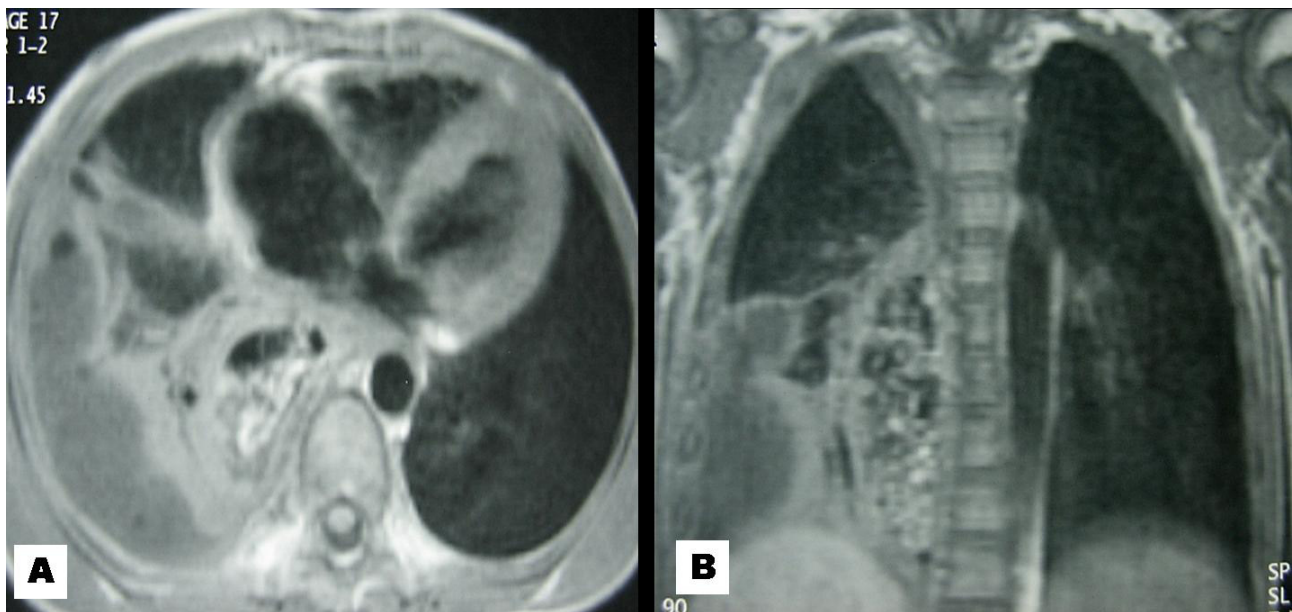

Figure 2. Chest MRI shows right-sided paravertebral pus.(A,B)

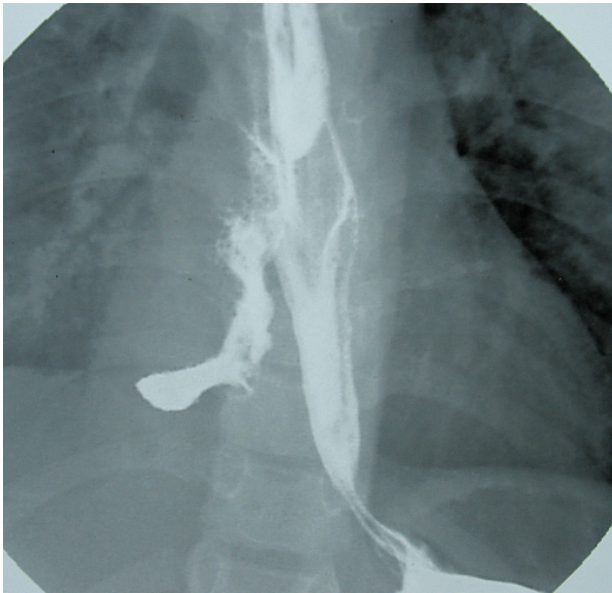


Figure 3. Esophagography shows thoracic esophageal perforation.

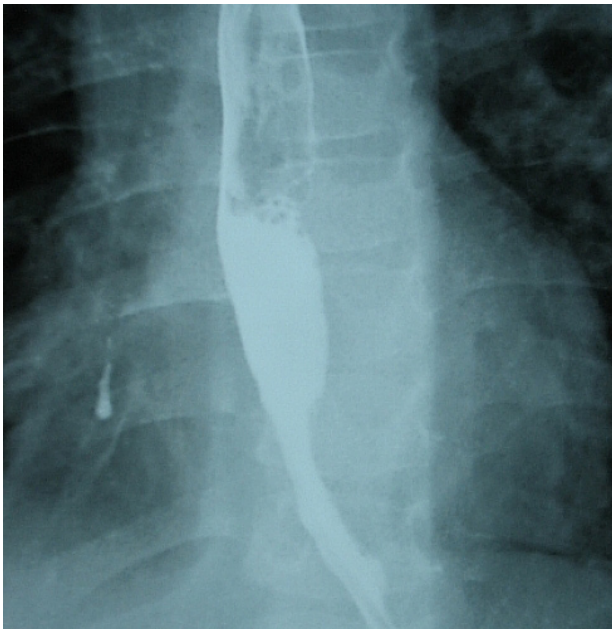


Figure 4. Postoperative control esophagography.

all efforts, fever, high level of white blood cell count persisted. Surgical management was planned to control septic origin and effective drainage of pleural space. Right-sided thoracotomy was performed at the 7th day of the hospital stay. Esophageal perforation of 7 cm length was seen between azygous vein and diaphragm. There was no emphysema thoracis. Primary closure of the esophageal perforation was planned intraoperatively. The layers were sutured primarily and separately after muscular and mucosal debridement. Reinforcement of the primary repair was done with pleural and intercostal muscle flaps. The esophagus was tied with absorbable catgut sutures at proximal and distal parts of the perforation to block the esophageal passage. Chest tubes were placed for drainage. Gastrostomy and jejunostomy were performed for nutrition. Chest tube drainage yielded *Pseudomonas*

aeruginosa growth during the postoperative course. Vital signs became normal at the 10th day of postoperative course. Chest tubes were ended at the postoperative 9th and 18th days. Oral feeding was started at the postoperative 25th day after esophagography revealed normal esophageal passage (Figure 4). Patient was discharged home at the 42nd day of the hospital stay (35th day of the postoperative course). He was well at 8 week follow-up postoperatively.

Discussion

Esophageal perforations are the most fatal injuries of the alimentary tract. The majority of blunt esophageal injuries involve the cervical esophagus with intrathoracic esophageal injuries, which are rare. The majority of the intrathoracic esophageal perforation from blunt trauma occurs in adults, as a result of high-speed motor vehicle accidents [2-4]. Thoracic esophageal perforation is a closed space where an infection is more difficult to treat and can rapidly lead to mediastinitis and sepsis. Some diagnoses are only made at autopsy [5]. The present case had intrathoracic esophageal perforation secondary to blunt trauma. Despite high morbidity and mortality rates, we report a case of successful management.

Diagnosis of an esophageal injury is extremely difficult following thoraco-abdominal trauma. The perforation is often non-specific and is easily confused with other disorders. The signs and symptoms of the perforation depend on the location, the cause of the trauma. Major symptoms and clinical signs include pain, subcutaneous air, dysphagia, dyspnea, and blood in the nasogastric tube [6]. However, these signs and symptoms have lack specificity in blunt trauma patients. Computed chest tomography helps to diagnose. Diagnosis is confirmed by using contrasted esophagogram or endoscopy or both. Early diagnosis is essential in esophageal perforation. However, in our case, the early diagnosis could not be achieved.

Treatment options include medical or surgical interventions. Various factors have important impacts on the treatment approach. These are as follows: the cause and the location of the perforation, the presence of underlying esophageal disease, the time interval between the perforation and diagnosis, and the age and general status of the patient. Primary closure within 24 hours is the most effective method of treating esophageal perforation. Surgical management must be individualized according to the size of the defect, degree of inflammation, contamination and the overall condition of patient [1-6]. Kiernan reported that early diagnosis (<24 h) combined with aggressive surgical treatment showed a hospital survival of 93% while late diagnosis (>24 h) increased mortality (30%), but even when diagnosis was >24 h the mortality was decreased to 10% when combined with surgery [7]. Surgical interventions may

include an esophageal resection or exclusion, debridement, esophageal repair, reinforcing the repair using adjacent tissues, drainage, diversion and nutrition when possible are key of healing in esophageal injuries.

In our case, despite delayed diagnosis, surgical interventions included debridement, primary repair of the esophageal perforation, blocking esophageal passage with absorbable sutures, reinforcing the repair with pleura and intercostal muscle, drainage and feeding via gastrostomy

and jejunostomy were all successful factors in the management.

In conclusion, esophageal rupture due to external blunt trauma is extremely rare in children. Physicians should pay attention to esophageal injury in blunt thoraco-abdominal trauma. Despite delayed diagnosis, primary surgical repair has a significant role in the successful treatment as in our patient.

References

1. Rajendra K, Ghritlaharey RK, Jain AK, Gupta G, Kushwaha AS. Intrathoracic esophageal rupture following blunt trauma chest in a ten months old girl. *J Indian Assoc Pediatr Surg* 2006; 11: 101-2.
2. Sartorelli KH, McBride WJ, Vane DW. Perforation of the intrathoracic esophagus from blunt trauma in a child: Case report & review of the literature. *J Pediatr Surg* 1999; 34: 495-7.
3. Karman MK, Lawrence HR. Managing an esophageal tear from blunt trauma. *Contemporary Surg* 2008; 64: 131-4.
4. Aagard J, Kjaergaard H. Treatment of iatrogenic esophageal perforation diagnosed with delay. *Ann Chir Gynaecol* 1991; 80: 346-8.
5. Nakai S, Yoshizawa H, Kobayashi S, Mihachi M. Esophageal injury secondary to thoracic spinal trauma: the need for early diagnosis and aggressive surgical treatment. *J Trauma* 1998; 44: 1086-9.
6. Glattner MS Jr, Toon RS, Ellestad G, McFee AS, Rogers W, Mack JW. et al. Management of blunt and penetrating external esophageal trauma. *J Trauma* 1985; 25: 784-92.
7. Kiernan PD, Sheridan MJ, Elster E, Rhee J, Collazo R, Byrne WD. et al. Thoracic esophageal perforations. *Southern Med J* 2003; 96: 158-63.